

Treatment of Basal Cell Carcinoma: A Focus on the Role of Mohs Micrographic Surgery

Ciara Maguire

Fifth Year Medicine, TCD

Clinical Points:

- Basal Cell Carcinoma (BCC) is the most common cancer worldwide and is most likely to occur on the sun-exposed areas of the head and neck in fair-skinned patients over the age of forty.
- While almost never metastasising, it can be extremely locally invasive and cause functional and cosmetic compromise.
- Mohs Micrographic Surgery is a specialised technique used to treat BCCs in which horizontal slices of the excised tissue are examined microscopically as opposed to the typical vertical slices of standard surgery.
- This allows for examination of 100% of the margins to look for residual tumours and therefore decreases the likelihood of recurrence and increases tissue sparing which is essential for a good cosmetic result.

ABSTRACT

Basal Cell Carcinoma (BCC) is the most common cancer in human and the leading cutaneous malignancy of the fair skinned Irish population. Mohs Micrographic Surgery is a specialised operational technique used in the treatment of BCC. It involves excision of the cancer and microscopic examination of 100% of the surgical margins. It has the highest cure rate of any treatment for BCC and the best cosmetic outcome as it does not sacrifice unnecessary surrounding tissue.

INTRODUCTION

Basal Cell Carcinoma (BCC) is a malignant neoplasm of epithelial cells, making up about 75% of all nonmelanoma skin cancers. It is the most common human malignancy (1). There are three main histological types: 1) nodular BCC, also known as "rodent ulcer", accounting for 60% of all BCCs, 2) superficial BCC, which is the next most common, comprising up to 15% of all BCCs (2) and 3) sclerosing/morpheaform BCC. In general, BCC is not an aggressive form of cancer, remaining localised with a very low rate of metastases (0.0028% to 0.55%) (3). However, if neglected, BCCs persist, enlarge, ulcerate and subsequently invade and destroy surrounding structures which may result in significant functional and cosmetic morbidity. The clinical course is generally unpredictable with aggressive, rapid extension from the outset, with the tumour growing only gradually or in spurts punctuated by partial regression (4).

Although BCCs can occur anywhere on the body, up to 85% are encountered on sun-exposed areas such as the face, scalp, ears and neck. Of these, the nose is the most commonly affected site, accounting for 25-30% of all BCCs. BCCs may occasionally complicate venous stasis ulcers, arteriovenous (AV) malformations, port wine stains or skin/hair graft transplantations or arise from scars of variable aetiology e.g. surgical, burn, post vaccination or post infection by *Leishmania* or *Varicella* (5).

The relationship of exposure to ultraviolet (UV) light, which is the most important risk factor, and development of BCCs is complex; showing strong associations to intermittent (recreational) sun exposure, especially exposure in early life (6). Those with fair skin (skin types 1 and 2) are at highest risk; particularly those of Scottish, Celtic or Scandinavian descent (7). BCCs can occur at any age but incidence increases after forty years of age (8) and men are slightly more commonly affected than women (1.2:1)

(9). A UK study also indicates that higher social classes are also at increased risk (10). In this review, the treatment of BCC with a specific look at Mohs Micrographic Surgery (MMS) is discussed.

WHAT ARE THE TREATMENTS FOR BCC?

Both medical and surgical treatment options for BCC are available (2). Medical treatments include radiation therapy, CO₂ laser treatment, photodynamic therapy, topical and intralesional chemotherapy with 5-fluorouracil and intralesional chemotherapy with interferon alpha or imiquimod. Surgical options include standard surgical excision, which is the most commonly used method (11), cryosurgery, curettage and electrodesiccation (C & E) and MMS.

According to a recent review (12) which compared these treatment modalities *radiation therapy* demonstrates five year cure rates (FYCR) of 90-93% in small, localised tumours, however it is less successful in the treatment of larger or invasive BCC. It also has a less favourable cosmetic outcome compared to C & E and surgical excision. *Photodynamic therapy* and topical intralesional chemotherapy with 5-fluorouracil are both only suitable for use in superficial tumours, as success is limited by their depth of penetration. *Imiquimod*, as monotherapy, has lower success rates in eradicating BCC compared to surgical excision, C & E and MMS, however it can improve the cure rates of other treatment modalities if used as an adjuvant. *Cryosurgery* has a FYCR of 93% for BCC. C & E has an FYCR of 92% in primary BCC, which varies depending on tumour size and is more successful in the treatment of small, localised tumours. *Standard surgical excision* has FYCR of 95% for primary BCC and 83% if recurrent BCC. The technique, although a cost-effective and usually successful method for treatment of low-risk tumours, does not involve histological examination of 100%

of the surgical margin and there is increased risk of recurrence in high risk BCC. *MMS* is the gold standard treatment for BCC (12), with a recurrence rate of only 1% in primary BCC. Although it may cost more than other methods, this may be mitigated by a reduction in tumour recurrence and the costs of re-treatment. Other studies have found that *MMS* has the lowest recurrence rates when compared to all other treatment modalities, especially in the case of recurrent BCC (13), where rates are only 6-10% (14).

WHAT IS MMS AND WHY IS IT SUITABLE FOR TREATMENT OF BCC?

Classical chemosurgery, the technique which later evolved into *MMS*, was first described in 1941 by Dr Frederick E Mohs. *MMS* is a highly specialised operative technique used in the removal of high risk BCC and many other cutaneous lesions e.g. squamous cell carcinoma (depending on type and location), keratoacanthoma, dermatofibrosarcoma protuberans and verrucous carcinoma (see Table 1) (15). It is performed as a day case under local anaesthetic by a dermatologist who has undergone additional training in a one to two year fellowship, rather than by a surgeon because of the necessary understanding of pathology and cutaneous oncology.

Two major innovations were characteristic of Mohs original technique:

- i) Examination of 100% of the excised tissue margin, as opposed to the standard vertical "breadloaf" technique which may only allow 0.1% of the surgical margin to be examined (16).
- ii) Preference for healing by second intention, that is, without wound closure, which results in a more acceptable cosmetic result, particularly on concave areas (2). This is still a simple, cost-effective choice today (preferred method of wound repair in 23-33% of cases) despite the predominance of more complex methods of wound repair (17).

MMS is a very suitable a treatment for BCC due to the careful mapping technique and horizontal sectioning. Minimal sacrifice of normal tissue allows retention of function and optimal cosmetic results on the areas affected, which with BCCs are most likely the head and neck, regions of great aesthetic importance to the patient. The procedure is carried out in stages, or Mohs layers, in which successive layers of tissue are excised and examined microscopically for residual tumour. The number of layers required to remove the tumour depends on its subclinical extension (18). *MMS* is constantly evolving and there have been a number of recent exciting developments regarding the standard technique, including employment of immunohistochemical stains to improve visualisation of tumour extension (19), the intra-operative delineation of tumour margins using multispectral dye enhanced polarized light imaging (20) and the use of real-time confocal reflectance microscopy to obviate the need for creation of frozen sections (21).

- Recurrent non-melanoma tumour (especially common in the "H" zone of the face where embryonic fusion planes meet and where sacrifice of the least amount of uninvolved tissue is paramount)
- Large tumours (>2cm)
- In high risk anatomic locations (periorbital, perinasal, preauricular, perioral)
- In aggressive histological subtypes (morpheaform/sclerosing, metatypical, micronodular, or fibrosing BCC)
- In anatomic sites where tissue preservation is imperative (fingers, genitals)
- Tumours with poorly defined clinical borders
- Tumours arising in irradiated skin
- In immunosuppressed patients
- Tumours with positive margins on prior excision (incompletely excised lesion)
- Tumours in chronic scar (Marjolin's ulcer)
- Naevoid BCC syndrome
- Tumours in Xeroderma pigmentosum
- In perineural invasion
- Tumours in Bazex syndrome

Table 1: Indications for *MMS* in the treatment of BCC.
Adapted from Dermatology, Bologna et al, 2003 (2)

MMS METHOD (22, 23)

MMS begins with excision of a previously debulked (by curettage) tumour and a variable margin of normal appearing surrounding skin using a scalpel angled at 45 degrees away from the tumour. This allows a progressively more bevelled incision with eventual undercutting of the tumour so that the excised tissue is saucer shaped (see Fig.1A.). The specimen and surrounding skin are marked with scalpel cuts (hash marks) for orientation prior to removal (see Fig.1B.) and are carefully plotted on a micrographic map. The wound is dressed and the patient returns to the waiting room while the specimen is processed by the histotechnician. This involves dividing it along the hash marks, usually into 2-4 pieces of 0.5-1.5 cm each (see Fig.1C.), using coloured dyes e.g. merbromin

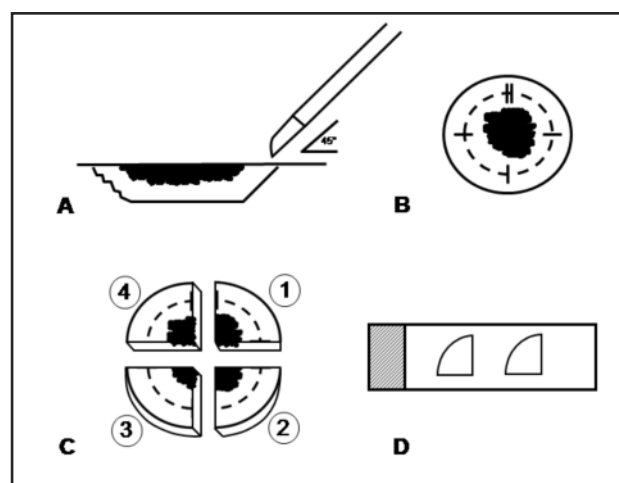


Fig. 1. Overview of steps in Mohs Micrographic Surgery.

(Mercurochrome) to mark the non-epidermal edges to preserve proper orientation (noting this on the map also), and subsequently inverting it and using a heat extractor to embed it deep side up in an optimum cutting temperature compound. This flattens it such that the epidermal margin and the deep tissue plane are on the same level. A cryostat is then used to cut 4-7 micrometre frozen sections, which are assembled on slides from deep to superficial and examined under the microscope (see Fig.1D.).

If residual tumour is found, it is noted on the map and a subsequent Mohs layer is done, re-anaesthetising the patient and removing additional tissue only from the area indicated on the map to contain residual tumour. This process is repeated until all margins are free of tumour. The wound is then either dressed and allowed to heal by second intention or closed immediately, using primary layered closure or local skin flaps and grafts, followed later by further reconstruction if necessary. Post-operative radiation therapy may be indicated in cases where complete tumour clearance is unachievable.

Post operative reviews are carried out at six weeks to ensure proper wound healing and contraction and at three months to monitor recurrence. During this time, patient education regarding limiting UV exposure is important. Annual surveillance for new primary and recurrent cancer is recommended for all patients, given that 30-50% of those with non-melanoma skin cancer will experience another skin cancer within five years (24).

COMPLICATIONS OF MMS

Complications with MMS are rare; evaluation of 1358 consecutive cases in the Duke University MMS unit revealed a low incidence of surgical complications (1.64%), mainly involving haemostasis (25). Intraoperative complications include anxiety, pain due to local anaesthetic injection, bleeding, nerve damage (sensory/ motor), particularly with BCCs located in the vicinity of the temporal branch of the facial nerve and allergic reactions. Careful

preoperative assessment of the patient and planning of the procedure can do much to avoid these complications.

Post operative complications include post operative bleeding, haematoma/seroma formation, infection, necrosis, wound dehiscence and scarring. The incidence of these complications may be reduced by meticulous haemostasis during surgery, pressure bandages and post operative wound care by the patient. The rate of clinically significant infection after MMS is very low (only one patient in the Duke University MMS study) but prophylactic antibiotics may be prescribed if deemed necessary due to tumour site.

COST-EFFECTIVENESS OF MMS

Due to the fact that increased resources are required in order to perform MMS, it is argued that the expense in terms of both the time and money involved precludes its widespread introduction as first line treatment for BCCs over SSE. A recent Dutch study concluded that MMS was not a cost-effective treatment of either primary or recurrent BCCs, with a mean difference in total costs of €254 for primary BCCs and €249 for secondary BCCs for MMS versus standard surgical excision (26). The mean total cost of BCC removal using MMS was €1137 for primary BCCs and €1146 for recurrent BCCs. Total costs included pre-operative, theatre-related and post-operative costs. However several limitations of this study have been pointed out (27, 28) and further studies are required.

CONCLUSION

MMS is evolving as a surgical technique that will be increasingly in demand with the epidemic rise in cutaneous cancers in Ireland. Despite this evolution, the two basic principles guiding MMS since its inception are maintained – precise margin control and tissue conservation. MMS is predicted to remain the gold standard for removal of non-melanoma skin cancers such as BCC.

REFERENCES

1. Anthony ML. Surgical Treatment of Nonmelanoma Skin Cancer. *A.O.R.N. J.* 2000;71(3):552-4,556-8,560-4
2. *Dermatology. Volume 2.* Bologna, Jorizzo, Rapini. 2003
3. Rubin AI, Chen EH, Ratner D. Basal-Cell Carcinoma. *N. Engl. J. Med.* 2005;353(21):2262-9
4. Evidence Based Dermatology. Edited by Hywel Williams, Michael Bigby, Thomas Diepgen, Andrew Herxheimer, Luigi Naldi, Berthold Rzany. 2003. Chapter 26 p. 325
5. Pathology of the Skin with Clinical Correlations, Volume 2. McKee, Calonje, Granter. 2005. Chapter 22 p. 1169
6. Armstrong BK, Kricger A. The epidemiology of UV induced skin cancer. *J. Photochem. Photobiol. B.* 2001;63:8-18
7. Cutaneous Medicine and Surgery: An integrated program in dermatology, Volume 2. Arndt, Le Boit, Robinson, Wintroub. 1996. Chapter 141 p.1387
8. Skin Disease: Diagnosis and Treatment. Habif, Campbell Jr., Chapman, Dinulos, Zug. 2005. Chapter 17 p. 424
9. Ramachandran S, Fryer AA, Lovatt TJ, Smith AG, Lear JT, Jones PW, Strange RC. Combined effects of gender, skin type and polymorphic genes on clinical phenotype: use of rate of increase in numbers of basal cell carcinomas as a model system. *Cancer Letters.* 2003;189 (2):175-81
10. Lear JT, Tan BB, Smith AG et al. Risk Factors for basal cell carcinoma in the UK: case-control study in 806 patients *J. R. Soc. Med.* 1997 Jul;90(7):371-4
11. Tilli CM, Van Steensel MA, Krekels GA, Neumann HA, Ramaekers FC. Molecular aetiology and pathogenesis of basal cell carcinoma. *Br. J. Dermatol.* 2005 Jun;152(6):1108-24
12. Neville JA, Welch E, Leffell DJ. Management on nonmelanoma skin cancer in 2007. *Nat. Clin. Pract. Oncol.* 2007 Aug;4(8):462-9
13. Lawrence. Mohs Micrographic Surgery for Basal Cell Carcinoma. *Clin. Exp. Dermatol.* 1999;24(2):130-3
14. Ceilley RI, Del Rosso JQ. Current modalities and new advances in the treatment of basal cell carcinoma. *Int. J. Dermatol.* 2006 May; 45(5):489-98
15. Darmstadt GL, Steinman HK. Mohs Micrographic Surgery of the Head and Neck. *West J. Med.* 1990;152(2):153-8
16. Otley CC, Salasche SJ. Mohs Surgery: efficient and effective. *Br. J. Ophthalmol.* 2004;88(9):1228
17. Moreno-Arias GA, Izento-Menezes CM, Carrasco MA, Camps-Fresneda A. Second Intention Healing after Mohs Micrographic Surgery. *J. Eur. Acad. Dermatol. Venereol.* 2000 May;14(3):159-65
18. Batra RS, Kelley LC. Predictors of Extensive Subclinical Spread in Nonmelanoma Skin Cancer treated with Mohs Micrographic Surgery. *Arch. Dermatol.* 2002;138(8):1043-51
19. Smith SB, Farley MF, Albertini JG, Elston DM. Mohs Micrographic Surgery for Granular Cell Tumor using S-100 Immunostain. *Dermatol. Surg.* 2002 Nov; 28(11):1076-8
20. Yaroslavsky AN, Neel V, Anderson RR. Demarcation of Nonmelanoma Skin Cancer Margins in Thick Excisions Using Multispectral Polarized Light Imaging. *J. Invest. Dermatol.* 2003;121(2):259-66
21. Rajadhyaksha M, Menaker G, Flotte T, Dwyer PJ, González S. Confocal examination of nonmelanoma cancers in thick skin excisions to potentially guide Mohs Micrographic Surgery without frozen histopathology. *J. Invest. Dermatol.* 2001;117(5):1137-43
22. *Surgery of the Skin: Procedural Dermatology.* Robinson, Hanke, Sengelmann, Siegel. 2005. Chapter 48
23. *Textbook of Dermatologic Surgery.* Ratz, Geronemus, Goldman, Malsney, Padilla. 1998 Chapter 25
24. www.nccn.org/professionals/physician_gls/PDF/nmsc.pdf National Comprehensive Cancer Network Clinical Practice Guidelines in Oncology: Basal Cell and Squamous Cell Skin Cancers V.1.2008
25. Jonathan L. Cook, Jennifer B. Perone. A Prospective Evaluation of the Incidence of Complications Associated with Mohs Micrographic Surgery. *Arch. Dermatol.* 2003;139:143-52
26. Essers BAB, Dirksen CD, Neiman FHM et al. Cost-effectiveness of Mohs micrographic surgery Vs surgical excision for basal cell carcinoma of the face. *Arch. Dermatol.* 2006 Feb;142(2):187-94
27. Otley CC. Cost-effectiveness of Mohs micrographic surgery Vs surgical excision for basal cell carcinoma of the face. *Arch. Dermatol.* 2006 Sep;142(9):1235
28. Chren MM. Determining the Value of Surgical Therapies for Basal Cell Carcinoma. *Arch. Dermatol.* 2006 Feb;142(2):231-2

ACKNOWLEDGEMENTS

Many thanks to Dr. Patrick Ormond, consultant dermatologist, St. James's Hospital, Dublin.