

# A Case of Disseminated Tuberculosis Disease with Associated Vitamin D Deficiency in a 26-Year Old Indian Man

Shane O'Neill\* and Emma Nolan\*

## CLINICAL POINTS

Tuberculosis (TB) is an infectious granulomatous disease that is predominantly caused by *Mycobacterium tuberculosis*. It usually affects the lungs (pulmonary TB), but can affect almost any organ in the body (disseminated TB).

Tuberculous meningitis is the most severe form of disseminated TB, with a mortality of 20-30%. Survivors may also experience significant morbidity including hydrocephalus, stroke, cranial nerve deficits and vasculitis.

The innate immune response against TB has recently been shown to be Vitamin D dependent. Binding of Vitamin D with its receptor leads to the production of the antimicrobial peptide cathelicidin, which induces the destruction of the bacteria.

Vitamin D deficiency has been shown to confer an increased susceptibility to tuberculosis.

Certain ethnic groups in which Vitamin D deficiency is prevalent (African American, Indian and Asian) demonstrate an increased susceptibility to the disease.

## Presentation of case

Mr. SRS, a 26-year old Indian man living in Ireland for the past five years, presented to an Accident and Emergency (A&E) Department as a general practitioner (GP) referral following a three-day history of pyrexia, headache, neck stiffness and back pain. The pain was localized to the middle of his head and around his eyes, and described as severe in nature with a severity grading of 10/10. He experienced associated vomiting and lethargy, however he had no photophobia or rash. No history of weight loss was reported, and there were no other positive findings on review of systems.

On admission to A&E Mr. SRS's temperature was 36.0°C, and he had a blood pressure of 111/67 mmHg, heart rate of 99 beats per minute, respiration rate of 16 breaths per minute, and an oxygen saturation of 96% on room air. His cranial nerve examinations II-XII were grossly normal except for partial deafness in his right ear, and his Glasgow Coma Scale was 15/15. Examination of all other systems was normal, and he was admitted under the care of the Infectious Disease Team.

Nine weeks previously, Mr. SRS presented to his GP with a two-week history of persistent pyrexia (38°C) and fatigue. Initially he was treated with Amoxicillin 500mg, which was subsequently substituted for Clarithromycin 500mg. Neither of these antibiotics improved his symptoms however, and Mr. SRS's GP then referred him to A&E (eight weeks prior to current presentation). He had no history of cough, sputum production or respiratory symptoms at the time. Before treatment was completed in hospital, Mr. SRS took his own discharge against medical advice to visit India. Whilst there he deteriorated again, the pyrexia returned and a papular eruption developed on both hands and feet. He attended a hospital in Delhi for further investigations.

Mr. SRS returned home to Ireland four weeks later and presented to A&E the following week (three days previous to current presentation) complaining of ongoing pyrexia and back pain. He was discharged and given an outpatient appointment for the Infectious Disease Team. However, in the intervening period he developed new symptoms including severe headache and neck stiffness, which led to

his current admission to A&E.

Aside from a prolonged childhood illness when he was eight years old that resulted in partial deafness in his right ear, past medical history was nil of note, as was family history. Currently, he was taking no medications and he had no known drug allergies.

Mr. SRS works as a business analyst and lives with his fiancée in Dublin. He is a non-smoker, has a moderate alcohol intake and has no history of illicit drug use. Ten months prior to current presentation he had been in India for one month. He reported that he was not aware of coming into contact with any persons with tuberculosis (TB) either in Ireland or India.

## Investigations and diagnosis

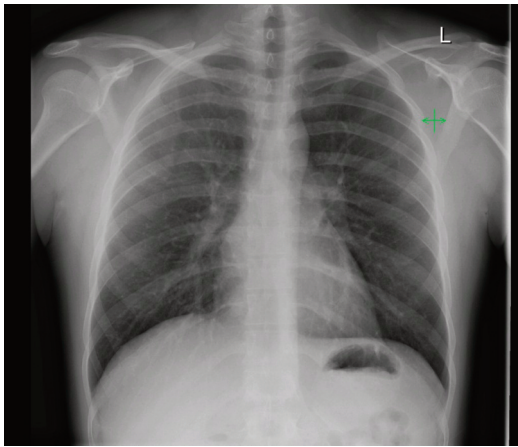
On the first admission to A&E, eight weeks previous to current presentation, Mr. SRS's blood tests revealed a decreased lymphocyte count, raised Liver Function Tests (LFTs), and both an elevated Erythrocyte Sedimentation Rate (ESR) and C Reactive Protein (CRP) of 22 and 24, respectively. All other full blood count (FBC) parameters were normal, along with his urea and electrolytes. A viral screen was carried out which was negative for HIV (Human Immunodeficiency Virus) antibody, Hepatitis B+C, Epstein Barr Virus and Cytomegalovirus. Due to his recent travel to India and his ongoing pyrexia, a malaria screen was performed but returned as negative. His coagulation and autoimmune screens were normal, however an immunological test revealed an increased IgA level. A chest X-ray detected no abnormality. A Mantoux test revealed a positive TB finding, with Mr. SRS having an induration of 17mm. Blood cultures were negative and a urine sample was sent for TB culture. However, at this stage Mr. SRS took his own discharge and returned to India.

While in India Mr. SRS had a number of repeat investigations at a hospital in Delhi. Of note he had a skin biopsy of a lesion on his hand, which was diagnosed as Leukocytoclastic Vasculitis (a non-specific inflammation of small vessels in the skin). An ultrasound of his abdomen was normal and an Elisa test for TB IgM (immunoglobulin M) was negative.

On presentation to A&E three days prior to current admission, Mr. SRS's routine blood tests revealed that his ESR and CRP remained elevated. His LFTs, however, had normalised, except for a raised lactate dehydrogenase (LDH). At this point he was discharged with a return appointment as an outpatient.

On current presentation Mr. SRS was placed in negative pressure isolation due to his urine sample from the first admission being culture positive for fully sensitive *Mycobacterium TB*, suggesting Disseminated TB. However, three sets of sputum samples were subsequently smear and culture negative for Pulmonary TB, and isolation precautions were removed. A repeat Chest X-ray had no abnormality noted (see Fig 1). A lumbar puncture was performed and a cerebrospinal fluid (CSF) sample obtained, due to his history of headache and neck stiffness. →

\*3rd Year Medicine, TCD



▲ **Fig. 1. Chest X-Ray.**  
No abnormality detected.

A clinical diagnosis of TB meningitis was made based on the CSF findings including a raised White Cell Count (110 per CMM), increased differential of mononuclear cells (99%) and an increased protein level (93mg/dl). The diagnosis was later confirmed by CSF culture. CT brain showed a small arachnoid cyst in the posterior fossa with no other abnormalities seen (see Fig. 2). Mr. SRS complained of persistent back pain, thus a Positron Emission Tomography (PET) scan was carried out to investigate any TB metastases to his bone. No abnormality was detected.

Due to his Indian ethnicity and the associated high risk of deficiency, a 25-Hydroxyvitamin D serum assay was done. It revealed a significant deficiency with a value of 19nmol/litre. The testing of Vitamin D levels is not part of the routine management of patients with TB at the present time. However, the rationale behind its inclusion in this case and its potential future relevance in TB management is considered in the discussion.

### Management

Mr. SRS received Paracetamol as an oral analgesic and anti-pyrexia. He was then commenced on a four-drug combination of Rifampicin, Isoniazid, Pyrazinamide and Ethambutol (RIPE). Standard treatment for TB meningitis, as recommended by the National Institute for Health and Clinical Excellence (NICE) guidelines<sup>1</sup>, is a 12 month regimen of RIPE for two months, followed by a further ten month regimen of the two drug combination Isoniazid and Rifampicin. Vitamin B6 supplementation was also given to prevent Isoniazid-induced neuropathy.

Adjunctive treatment with Dexamethasone 4mg TDS was given PO. According to the NICE guidelines<sup>1</sup>, the duration of treatment should last 2-3 weeks with a gradual dose reduction. Administration of corticosteroids along with antituberculous drugs in patients with TB meningitis has been shown to reduce both mortality and the associated neurological sequelae<sup>2</sup>, such as hydrocephalus, in survivors. It is believed that corticosteroids reduce the swelling of the meninges and relieve the intracranial pressure<sup>2,3</sup>. The major adverse effects of corticosteroid use include gastrointestinal bleeding, and suppression of the inflammatory response, which may provoke an unchecked growth of the bacteria. This puts vulnerable patients, such as those who are immunocompromised, at risk of serious infections. The Cochrane Review recommended that corticosteroids be routinely used in immunocompetent patients with TB meningitis. However, there is not enough evidence to support their use in immunocompromised patients<sup>2</sup>.

### Discussion

TB is one of the leading causes of morbidity and mortality globally and a staggering one third of the world's population is infected, with 8 million new cases per annum<sup>4</sup>. In Ireland the incidence is increasing and is currently 11.3 per 100,000<sup>5</sup>. TB is usually caused by the bacterium *Mycobacterium tuberculosis*. Spread of infection is via the inhalation of aerosolised droplets from a person infected with pulmonary TB. Infection can also occur via the ingestion of *Mycobacterium bovis* although this form of infection is rare since the advent of pasteurised milk. In extremely rare

cases the Bacille Calmette-Guerin (BCG) vaccine, an attenuated form of *Mycobacterium bovis*, can cause disseminated TB, usually several months post vaccination<sup>6</sup>.

Primary TB is a self-limited infection in 90% of cases. However, in 5% of patients the infection is not contained and leads to tuberculous disease in the form of progressive primary TB. This can affect the respiratory system in isolation or may result in systemic involvement via lymphohematogenous spread. This disseminated form can cause tuberculous disease in any organ, the most serious affecting the central nervous system in the form of TB meningitis. In the remaining 5% of cases the infection remains dormant and can be reactivated as secondary TB at a later stage<sup>7</sup>.

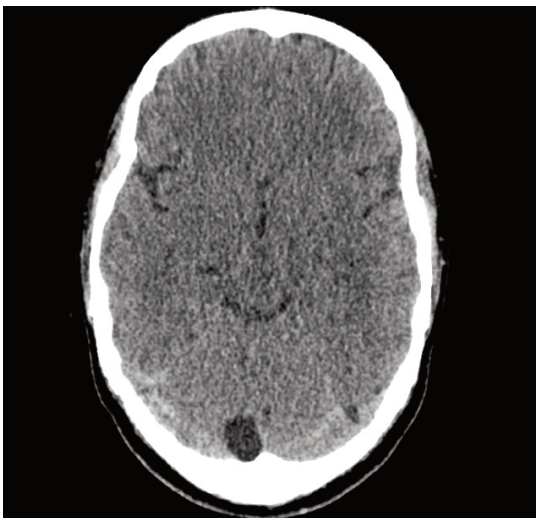
TB meningitis is a rare complication of tuberculous disease, with an incidence of 0.2 per 100,000 in Ireland in 2007<sup>5</sup>. It is a severe condition, having an overall mortality rate of 20-30%, and is associated with significant morbidity in survivors, with up to 40% suffering neurological deficits including hydrocephalus, cranial nerve deficits, vasculitis and stroke<sup>2,3</sup>.

The co-occurrence of Vitamin D deficiency and TB is of particular interest in this case study, wherein Mr. SRS had a significant deficiency of Vitamin D (serum concentration was 19nmol/L) and a diagnosis of TB meningitis. A recently elucidated link between Vitamin D status and TB offers a potentially plausible biological mechanism for increased susceptibility to the disease in this case, and may have implications for the future direction of TB research.

Looking back at the history of TB treatment in the pre-antibiotic era one can see the importance of sunlight in the Sanatorium movement (long term care facility for TB), the use of UV light for the management of Lupus vulgaris (a cutaneous form of TB) and the use of calciferol as a TB treatment in the 1940s<sup>4,8</sup>. All these practices may correlate to the recently elucidated Vitamin D-activated antimicrobial pathway.

Vitamin D is best known for its role in maintaining calcium and phosphate levels in the body. However 1,25-dihydroxyvitamin D, the biologically active form of Vitamin D, has also been shown to be an important immunomodulator<sup>8,9</sup>. In relation to TB infection, Vitamin D plays an integral part in the innate immune response against the pathogen<sup>4,10</sup>. This response is a non-specific defence mechanism against foreign pathogens, such as the bacterium causing TB, and monocytes and macrophages are vital blood-borne constituents within this system. When monocytes and macrophages come into contact with the lipopolysaccharide (antigenic component of the bacterial cell wall) of *Mycobacterium tuberculosis*, activation of Toll like receptors 1/2 (TLRs) or Nod-like receptors on the monocyte/macrophage surface leads to upregulation of both the Vitamin D Receptor (VDR) gene and the Cyp27B1 gene. The latter is responsible for the expression of the 25-hydroxyvitamin D-1 $\alpha$ -hydroxylase enzyme (1-OHase), which catalyses the conversion of inactive 25-hydroxyvitamin D to the active 1, 25-dihydroxyvitamin D form. This active form binds with the VDR leading to the increased production of the antimicrobial peptide cathelicidin (8, 11). This peptide is a key player in the innate immune response and induces the destruction of *Mycobacterium tuberculosis*<sup>11</sup>.

A concentration of 75nmol/L (30ng/ml) 25-hydroxyvitamin D is →



▲ Fig. 2. CT Brain. Small arachnoid cyst in posterior fossa.

necessary to give adequate substrate for 1-OHase. Levels less than 50nmol/L (20ng/ml), which lead to decreased active Vitamin D formation and thus decreased cathelicidin production, prevent the macrophage or monocyte from initiating the innate immune response against the microbe<sup>9</sup>.

There is currently no consensus on a reference range for normal Vitamin D levels in the body. Generally, serum Vitamin D readings of less than 50nmol/L (20ng/ml) are considered to imply deficiency, while 75-150nmol/L (30-60ng/ml) is considered to be sufficient<sup>12,13</sup>. Taking this into account it is clear that Mr.

SRS's measured serum Vitamin D level of 19nmol/L implies a considerable deficiency. Crucially, using these adopted limits of normality, there are an estimated 1 billion people worldwide with a Vitamin D deficiency<sup>14</sup>. Certain ethnic groups are affected more than others. In India, deficiencies have been reported in up to 90% of participants in some studies<sup>15</sup>. African Americans also have decreased levels of 25-hydroxyvitamin D. The proposed explanation for this increased prevalence of Vitamin D deficiency is that the increased melanin concentration in their skin absorbs UVB light, inhibiting the body's natural capacity for UV-dependent production of Vitamin D (16).

In keeping with the link between Vitamin D deficiency and impairment of innate immunity mechanisms, African Americans have been shown to exhibit increased susceptibility to and experience a more rapid and aggressive form of TB (17). Of significance, one particular study demonstrated that African American sera inoculated with fluorescent BCG, leading to TLR1/2 activation, produced significantly lower levels of cathelicidin compared to the Caucasian cohort. Interestingly, supplementation of the African American sera with physiological levels of 25-hydroxyvitamin D restored cathelicidin production<sup>8</sup>. A further link between Vitamin D and susceptibility to TB lies in the findings that some VDR polymorphisms offer a protective mechanism against TB whereas others have been shown to increase susceptibility. These findings may explain the differing levels of susceptibility to TB amongst different ethnic groups and also reinforce Vitamin D's importance in relation to this disease<sup>18,19</sup>.

Numerous studies have investigated the use of Vitamin D supplementation as an adjunct to modern antituberculous regimens. One such study demonstrated that when a single oral dose of 2.5mg Vitamin D was given to subjects, their serum subsequently exhibited enhanced immunity to mycobacteria in vitro<sup>20</sup>. Another placebo-controlled randomised trial investigating Vitamin D supplementation (0.25mg/day) over a 6-week period involving 67 patients with pulmonary TB revealed that 100% of subjects in the Vitamin D group had no evidence of *Mycobacterium tuberculosis* in their sputum compared to only 76.7% of the placebo group<sup>21</sup>. However, a recent review of Vitamin D in the treatment of pulmonary TB stated that "Current published studies... are generally inadequate to evaluate the efficacy of such treatment"<sup>22</sup>. More comprehensive clinical trials investigating the effectiveness of this potential treatment are necessary, particularly in light of the increasing prevalence of Multi-Drug Resistant (MDR) and

Extensively-Drug (XDR) Resistant strains of TB, as Vitamin D supplementation may be useful as a cost-effective adjunct to current TB management.

Given the historical clinical association and recent research findings, it has become clear that Vitamin D plays an integral role in increasing an individual's susceptibility to TB. Specifically, the recently elucidated biological mechanism of the innate immune response against TB, involving cathelicidin, has been shown to be Vitamin D-dependent. Vitamin D levels are currently not measured as part of the routine investigations for this disease. However, given this newly demonstrated relationship, routine testing may become a standard investigation, particularly in certain ethnic groups where the risk of Vitamin D deficiency is high. Deficiency in such groups may warrant a role for Vitamin D supplementation as an adjunct to current TB regimens. Although recent studies are encouraging, further research is needed to confirm the efficacy of this treatment option. This may prove to be particularly crucial with the increasing emergence of resistant strains of TB.

### Acknowledgements

The authors would like to thank Dr. Colm Bergin, Consultant Physician in St. James Hospital for his encouragement and support. ■

### References

1. National Institute for Health and Clinical Excellence (NICE) Tuberculosis: Clinical diagnosis and management of tuberculosis, and measures for its prevention and control. Royal College of Physicians of London 2006.
2. Prasad K, Singh MB. Corticosteroids for managing tuberculous meningitis. *Cochrane Database of Syst Rev* 2008;(1):CD002244.
3. Thavaites GE, Nguyen DB, Nguyen HD, Hoang TQ, Do TT, Nguyen TC et al. Dexamethasone for the treatment of tuberculous meningitis in adolescents and adults. *N Engl J Med* 2004;351(17):1741-51.
4. Liu PT, Modlin RL. Human macrophage host defense against *Mycobacterium tuberculosis*. *Curr Opin Immunol* 2008;20(4):371-6.
5. Provisional 2007 TB Data: A Report by the Health Protection Surveillance Centre. Health Service Executive 2008.
6. Mak TK, Hesselning AC, Hussey GD, Cotton MF. Making BCG vaccination programmes safer in the HIV era. *Lancet* 2008;372(9641):786-7.
7. Kumar V, Abbas AK, Fausto N. Robbins and Cotran: Pathologic Basis of Disease, 7th edition 2004.
8. Liu PT, Stenger S, Li H, Wenzel L, Tan BH, Krutzik SR et al. Toll-like receptor triggering of a vitamin D-mediated human antimicrobial response. *Science* 2006;311(5768):1770-3.
9. Holick MF. Vitamin D deficiency. *N Engl J Med* 2007;357(3):266-81.
10. Goswami R, Mishra SK, Kochupillai N. Prevalence & potential significance of vitamin D deficiency in Asian Indians. *Indian J Med Res* 2008;127(3):229-38.
11. Liu PT, Stenger S, Tang DH, Modlin RL. Cutting edge: vitamin D-mediated human antimicrobial activity against *Mycobacterium tuberculosis* is dependent on the induction of cathelicidin. *J Immunol* 2007;179(4):2060-3.
12. Holick MF. High prevalence of vitamin D inadequacy and implications for health. *Mayo Clin Proc* 2006;81(3):353-73.
13. Malabanan A, Veronikis IE, Holick MF. Redefining vitamin D insufficiency. *Lancet* 1998;351(9105):805-6.
14. Holick MF, Siris ES, Binkley N, Beard MK, Khan A, Katz JT et al. Prevalence of Vitamin D inadequacy among postmenopausal North American women receiving osteoporosis therapy. *J Clin Endocrinol Metab* 2005;90(6):3215-24.
15. Goswami R, Gupta N, Goswami D, Marwaha RK, Tandon N, Kochupillai N. Prevalence and significance of low 25-hydroxyvitamin D concentrations in healthy subjects in Delhi. *Am J Clin Nutr* 2000;72(2):472-5.
16. Matsuoka LY, Wortsman J, Haddad JG, Kolm P, Hollis BW. Racial pigmentation and the cutaneous synthesis of vitamin D. *Arch Dermatol* 1991;127(4):536-8.
17. Stead WW, Senner JW, Reddick WT, Lofgren JP. Racial differences in susceptibility to infection by *Mycobacterium tuberculosis*. *N Engl J Med* 1990;322(7):422-7.
18. Wilkinson RJ, Llewelyn M, Toossi Z, Patel P, Pasvol G, Lavvani A et al. Influence of vitamin D deficiency and vitamin D receptor polymorphisms on tuberculosis among Gujarati Asians in west London: a case-control study. *Lancet* 2000;355(9204):618-21.
19. Selvaraj P, Alagarasu K, Harishankar M, Vidyarani M, Narayanan PR. Regulatory region polymorphisms of vitamin D receptor gene in pulmonary tuberculosis patients and normal healthy subjects of south India. *Int J Immunogenet* 2008;35(3):251-4.
20. Martineau AR, Wilkinson RJ, Wilkinson KA, Newton SM, Kampmann B, Hall BM et al. A single dose of vitamin D enhances immunity to mycobacteria. *Am J Respir Crit Care Med* 2007;176(2):208-13.
21. Nursyam EW, Amin Z, Rumende CM. The effect of vitamin D as supplementary treatment in patients with moderately advanced pulmonary tuberculous lesion. *Acta Med Indones* 2006;38(1):3-5.
22. Martineau AR, Honecker FU, Wilkinson RJ, Griffiths CJ. Vitamin D in the treatment of pulmonary tuberculosis. *J Steroid Biochem Mol Biol* 2007;103(3-5):793-8.