

A Case Report of a Primary Small Cell Carcinoma of the Subglottis

Hazeem Ahmayuddin¹, Jamsari Khalid²

¹School of Medicine, Trinity College, University of Dublin, Ireland

²Department of Radiation Oncology, The Brunei Cancer Centre, Jerudong, Brunei Darussalam

Abstract

Small cell carcinoma (SmCC) is a type of cancer affecting the subglottic region of the larynx. Subglottic carcinomas represent only less than 5% of laryngeal cancers, with SmCC accounting for only 0.5%. This case report highlights a patient with a rapidly-progressing laryngeal growth that caused a significant airway obstruction within a period of three weeks. Further investigation revealed that the patient was suffering from a rare form of laryngeal neoplasm, which was consistent with a diagnosis of a limited stage primary SmCC of the subglottis. He was then started on a regimen of radiotherapy with concomitant chemotherapy (cisplatin and etoposide) for a duration of two months. Response to therapy was rapid, with a reduction in tumour size. A combination of radiotherapy and platinum-based chemotherapy is currently the modality of choice for treatment, with recent data showing that surgery has a limited role in laryngeal SmCC.

Introduction

Small cell carcinoma (SmCC) is an anaplastic, highly malignant carcinoma, primarily affecting the bronchogenic region of the lung. Histologically, it is composed of small ovoid cells with scanty neoplasm (Stedman, 1990). These cells are characterised by a dominant, deeply basophilic nucleus, with absent or indistinct nucleoli (Stedman, 1990). Small cell carcinoma (SCC) comprises over 95% of laryngeal cancers. The remaining 5% is made up by adenocarcinoma, sarcoma, miscellaneous carcinomas (adenoid cystic, neuroendocrine carcinoma etc.) and the rare variants of SCC – verrucous, spindle and basaloid SCC (Mastronikolis et al., 2008-12). SmCC, which is a subtype of neuroendocrine carcinoma accounts for approximately 0.5% of all laryngeal cancers (Sharma et al., 2014). With regards to location, glottic carcinomas represent the majority of laryngeal cancers (50%-60%), followed by the supraglottic

carcinomas (30%-40%), while the subglottic carcinomas are uncommon and comprise 5% or fewer of laryngeal cancers (Mastronikolis et al., 2008-12). Extrapulmonary small cell carcinoma follows a staging classification of either limited or extensive stage. Disease confined to a primary site with or without loco-regional lymph node involvement is classified as limited, while all others are classified as extensive (Doll, 2018).

There is a paucity of literature in this area, with only approximately 200 documented reports of laryngeal SmCC to date worldwide (Raposo et al., 2018). This is a significant barrier to understanding the presentation, progression, treatment and prognosis of this rare condition.

In this report, we examine a case of a subglottic laryngeal SmCC. The patient was treated with radiotherapy, with concomitant cisplatin and etoposide for a duration of 2 months.

Case presentation

A 45-year-old male first presented to the emergency department (ED) with a three-week history of fever, dyspnoea, wheeze and productive cough. The patient reported an acute deterioration of symptoms within the previous two days, with hemoptysis, barking cough and hoarseness of voice, and was diagnosed with a respiratory tract infection (RTI). He was admitted for antibiotic and steroid treatment and discharged after one day. The patient's Eastern Cooperative Oncology Group (ECOG) performance status score was deemed to be 1: symptomatic but ambulatory (Oken et al., 1982). He reported a consumption of four units of alcohol per week for an unknown duration, and a tobacco smoking history of 5.6 pack years. His only past medical history of note was gout.

Investigations

Following the initial presentation, the patient experienced a gradual exacerbation of his symptoms. Over a course of two weeks, the patient presented to ED three times, two times of which he required admission where he was again treated for a RTI. On the fourth hospital presentation, however, a decision was made for a nasal endoscopy to be performed. Endoscopic investigations showed a left subglottic mass causing severe airway compromise and a right vocal cord leukoplakia. This prompted emergency tracheostomy tube insertion. Physical examination found no evidence of cervical lymphadenopathy.

A biopsy of the left subglottic lesion showed a malignant neoplasm in the stroma. Histological examination of this neoplasm revealed cells with large, markedly hyperchromatic nuclei and scanty cytoplasm, forming cords and trabeculae. Mitotic activity was frequent and necrosis was present. Crush artefact and nuclear moulding were evident. There was no evidence of dysplasia in surface stratified squamous epithelium. Immunohistochemical analysis showed that the malignant cells had the following pattern: CKAE1/3 positive, LCA negative, synaptophysin positive, chromogranin negative and had a Ki67 proliferative index which stained >90% of the malignant cells. A computed tomography scan of the neck, thorax, abdomen and pelvis was performed in conjunction with a magnetic resonance imaging of the head and neck. They demonstrated a left-sided subglottic soft tissue mass measuring 2.34 x 1.84 x 1.46 cm which encroached upon and narrowed the lumen to 2.12 mm. There was also evidence of bilateral cervical lymphadenopathy, involving nodes at levels II and III, which ranged from 5.87 mm to 15.8 mm in size, being larger on the right side. There was no radiological evidence of distant metastasis from both imaging modalities. Blood investigation revealed nothing of note; and a test for chromogranin A read a level of 73 µg/L (0-100). A subsequent lymph node biopsy found them to be negative for metastasis. A diagnosis of limited stage primary SmCC of the subglottis was made. A separate biopsy of the right vocal cord leukoplakia was performed, which then showed squamous dysplasia. Two strips of stratified squamous epithelium was obtained from the site. One of the strips showed slightly thickened squamous epithelial cells with variable nuclear enlargement and hyperchromasia. Few mitotic figures were found in the lower half of the strip.

However, there was no evidence of invasive carcinoma from both strip specimens.

Treatment

The patient was subsequently started on a concurrent chemoradiotherapy regimen for a duration of two months. The chemotherapy was given in three cycles. Each cycle consisted of three days of chemotherapy administration. On the first day, the patient received intravenous (IV) etoposide and IV cisplatin, and IV etoposide for the second and third day. Each cycle of chemotherapy was to be given once every three weeks, however, the gap between cycles 2 and 3 increased by four days due to treatment complications which are outlined below. Dosages were administered proportional to body surface area, which was 1.8m².

A volumetric arc therapy (VMAT) technique was used to deliver external beam radiotherapy to a dose of 60 Gy at 2 Gy/ fraction. This was delivered five times per week for 6 weeks, totaling 30 fractions. The radiotherapy targeted neck nodes bilaterally as a prophylactic measure, as they are a common site of metastasis (Alpert et al., 2004).

Follow up

The patient was admitted due to complications one week after the second cycle of chemotherapy, following the development of transient neutropenia, thrombocytopenia and oesophagitis. The treatment was temporarily withheld, and the patient received symptomatic treatment, which included antibiotics. Once again, one week after completion of treatment, the patient developed febrile neutropenia and pneumonia. He was readmitted for IV antibiotics and granulocyte-colony stimulating factor (G-CSF). On both occasions, the patient did not require ICU admission. During treatment course, the patient developed radiation dermatitis around the collarbone region of the neck. Other common side effects related to radiotherapy such as mucositis, xerostomia, lymphedema and nausea was not reported. Otherwise, radiological evidence of tumour regression was pronounced (Figure 1).

Discussion

Laryngeal SmCC has been strongly linked to heavy smoking and drinking (Pointer et al., 2017). It is apparent, however, that the patient in this case report reported minimal tobacco and alcohol intake which may suggest another risk factor was at play. The patient's height is 161 cm and he weighs 74 kg, therefore his Body Mass Index (BMI) is 28.5. This would put him under the

classification of overweight. Studies have found that diet (Levi et al., 1998), environmental exposure (Sturgis & Pytynia, 2005), oral hygiene (Tezal et al., 2009), gastroesophageal reflux (Zainuddin & Mohd Kornain, 2016), premalignant lesions (Shaw & Beasley, 2016) and HPV infection (Li et al., 2013) are among other risk factors predisposing individuals to oropharyngeal/laryngeal cancer. Among these, the patient was positive

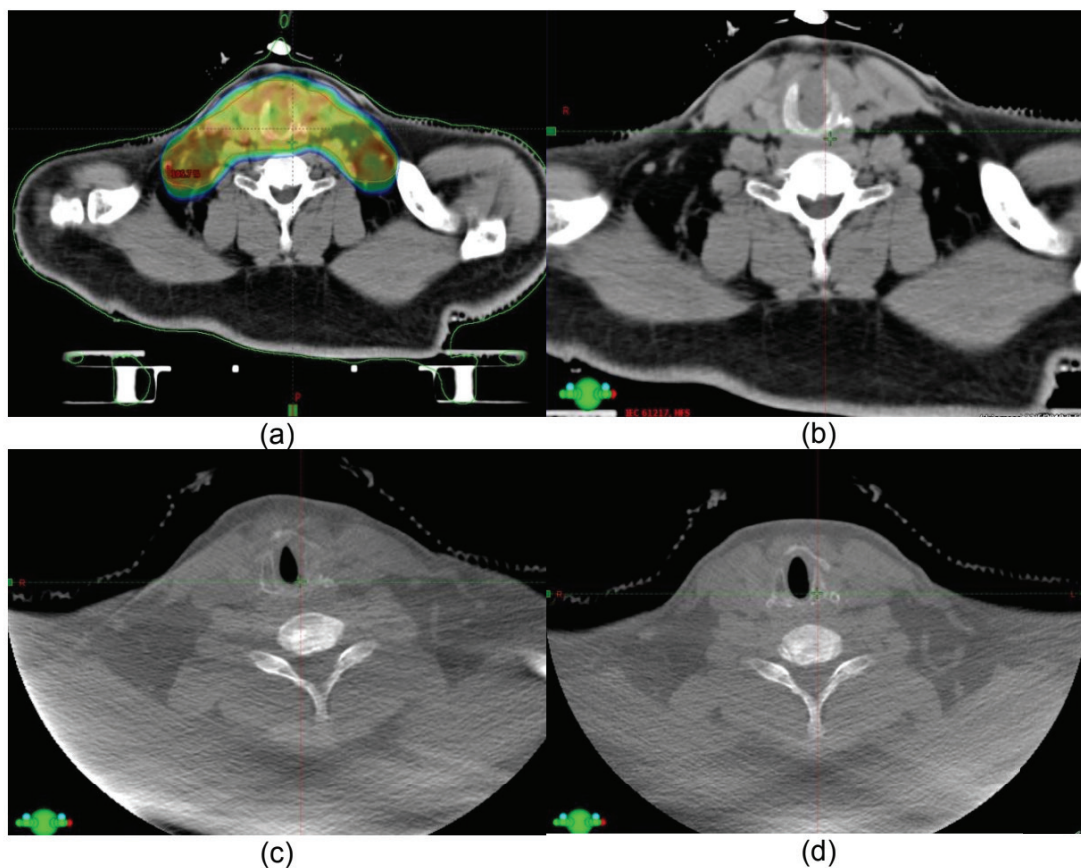


Figure 1: Pre-, middle and post-treatment progression of the lesion through computed tomography scan including an external beam planning for radiotherapy (a) External Beam Planning contour, (b) Pre-treatment, (c) Middle of treatment, (d) Post-treatment

Week 1							Week 2							Week 3						
M	T	W	Th	F	Sa	Su	M	T	W	Th	F	Sa	Su	M	T	W	Th	F	Sa	Su
Tx	Tx	Tx					Tx	Tx	Tx					Tx	Tx	Tx				
C,E	E	E					C,E	E	E					C,E	E	E				

Table 1. Example of chemotherapy regimereceived by the patient. Tx: Treatment day, C: IV Cisplatin, E: IV Etoposide

for premalignant lesion, which was leukoplakia present at his right vocal cord. Premalignant lesions such as leukoplakia or erythroplakia is very rarely caused by HPV-16 infection (Shaw & Beasley, 2016). Approximately 25% of epithelial biopsy will show dysplastic changes in leukoplakia affected areas (Shaw & Beasley, 2016) and this was histologically evident in our patient.

There are only two other well documented reports of primary small cell carcinoma affecting the subglottis, that is still in the limited stage in the medical literature today. Hence, it is important for every case to be reported so that we could learn its pattern of manifestation. The first case is a 68 year old female presenting with a one week history of progressive dyspnoea and hoarseness of voice with a background of three month history of chronic, non-productive cough (Johnson et al., 1979). The second case saw a 54 year old male presenting with a three month history of progressive dyspnoea with inspiratory stridor and concurrent multiple myeloma (Thompson et al., 1982). Both cases exhibit similar pattern of acute progressive dyspnoea being the chief complaint, which is similar to the patient we are reporting. It is worth highlighting that the patient in this case study also presented with barking cough - a symptom that is predominantly seen in the paediatric population caused by croup or laryngotracheitis. This phenomenon is rarely seen in the adult cohort and is certainly unorthodox to have presented in laryngeal neoplasm.

Historically, SmCC of the larynx follows a treatment regime of either surgery, radiotherapy, chemoradiotherapy or a combination of surgery, radiotherapy and adjuvant chemotherapy (Baugh et al., 1986). Currently, there are no available guidelines as to the management of laryngeal SmCC owing to its rarity. Management decisions have been based on small studies and case reports. Only recently, a meta-analysis found that the addition of surgery to chemotherapy and radiotherapy did not improve survival in patients with locally advanced disease, as compared to receiving only chemotherapy and radiotherapy (Pointer et al., 2017). Further, a retrospective study of 120 extra-pulmonary SmCC patients also concluded that surgical resection was not significantly correlated with recurrence-free or overall survival (SM et al., 2010). Despite the inability of chemotherapy to cross the blood-brain barrier (Wang et al., 2014), routine prophylactic cranial irradiation (PCI) is not recommended due to the low incidence (7.7%) of

metastasis to the brain among patients with laryngeal SmCC (Kumar et al., 2015).

There was rapid disease progression in this patient: within three weeks of symptom onset, the patient's airway had narrowed to an extent necessitating emergency tracheostomy. This could partially be explained by the high Ki-67 proliferative index, which is known to predict a worse prognosis in other malignancies (Hoos et al., 2001). Laryngeal SmCC has consistently been reported to have a poor prognosis. The latest data demonstrate a median survival of 17.0 months and a 2-year survival of 40.9%. Other studies have found the 2-year and 5-year survival rates to be 16% and 5% respectively (Pointer et al., 2017). Despite this dismal prognosis, there have been several cases reporting survival times of greater than 47 months. This patient cohort was treated with radiotherapy and concomitant chemotherapy with cisplatin and etoposide (Zhu et al., 2015). Indeed, a 2015 study reported a patient survival time of 99 months when treated with similar chemoradiotherapy regimen (Iqbal et al., 2015).

It is generally agreed, however, that despite concomitant chemoradiotherapy being the standard of care for laryngeal SmCC – it is far from ideal. Therefore, more data are still needed from larger trials and case reports, employing both conventional and more exploratory therapeutic regimes.

Conflict of interest

The authors declare that there is no conflict of interest regarding the publication of this paper.

References

- Alpert, T. E., Morbidini-Gaffney, S., Chung, C. T., Bogart, J. A., Hahn, S. S., Hsu, J., & Kellman, R. M. (2004). Radiotherapy for the clinically negative neck in supraglottic laryngeal cancer. *Cancer J*, 10(6), 335-338.
- Baugh, R. F., Wolf, G. T., Beals, T. F., Krause, C. J., & Forastiere, A. (1986). Small cell carcinoma of the larynx: results of therapy. *Laryngoscope*, 96(11), 1283-1290.
- Doll, D. C. (2018, Feb. 28, 2018). Extrapulmonary small cell carcinoma. Extrapulmonary small cell carcinoma. Retrieved from <https://www.uptodate.com/contents/extrapulmonary-small-cell-cancer>
- Hoos, A., Stojadinovic, A., Mastorides, S., Urist, M. J., Polsky, D., Di Como, C. J., . . . Cordon-Cardo, C. (2001). High Ki-67 proliferative index predicts disease specific survival in patients with high-risk soft tissue sarcomas. *Cancer*, 92(4), 869-874.
- Iqbal, M. S., Paleri, V., Moor, J., Dobrowsky, W., Kelly, C., & Kovarik, J. (2015). Small cell neuroendocrine carcinoma of larynx: case series and literature review. *J Laryngol Otol*, 129(9), 910-915. doi:10.1017/S0022215115001668
- Johnson, G. D., Abt, A. B., Mahataphongse, V. P., & Conner, G. H. (1979). Small cell undifferentiated carcinoma of the larynx. *Ann Otol Rhinol Laryngol*, 88(Pt 1), 774-778. doi:10.1177/000348947908800606
- Kumar, L. P., Armugam, N., Triveni, B., & Krishna, M. R. (2015). Neuroendocrine tumor of larynx: A review of literature. *Asian Journal of Oncology*, 1(1), 33-36. doi:10.4103/2454-6798.165092
- Levi, F., Pasche, C., La Vecchia, C., Lucchini, F., Franceschi, S., & Monnier, P. (1998). Food groups and risk of oral and pharyngeal cancer. *Int J Cancer*, 77(5), 705-709.
- Li, X., Gao, L., Li, H., Gao, J., Yang, Y., Zhou, F., . . . Jin, Q. (2013). Human papillomavirus infection and laryngeal cancer risk: a systematic review and meta-analysis. *J Infect Dis*, 207(3), 479-488. doi:10.1093/infdis/jis698
- Mastronikolis, N. S., Papadas, T. A., Goumas, P. D., Triantaphyllidou, I.-E., Theocharis, D. A., Papageorgakopoulou, N., & Vynios, D. H. (2008-12). Head and Neck: Laryngeal tumors: an overview. *Atlas of Genetics and Cytogenetics in Oncology and Haematology*, 2009(13(11)), 888-893. doi:DOI: 10.4267/2042/44625
- Oken, M. M., Creech, R. H., Tormey, D. C., Horton, J., Davis, T. E., McFadden, E. T., & Carbone, P. P. (1982). Toxicity and response criteria of the Eastern Cooperative Oncology Group. *Am J Clin Oncol*, 5(6), 649-655.
- Pointer, K. B., Ko, H. C., Brower, J. V., Witek, M. E., Kimple, R. J., Lloyd, R. V., . . . Baschnagel, A. M. (2017). Small cell carcinoma of the head and neck: An analysis of the National Cancer Database. *Oral Oncol*, 69, 92-98. doi:10.1016/j.oraloncology.2017.04.009
- Raposo, A., Marco, A., Garcia-Solano, M. E., Martinez-Ortiz, M. J., Garcia-Purrinos, F., & Lajara, J. (2018). Primary small cell carcinoma of the larynx. Survival time of 47 months. Case report. *Ann Med Surg (Lond)*, 30, 46-49. doi:10.1016/j.amsu.2018.04.031
- Sharma, J. D., Baishya, N., Rahman, T., Krishnatreya, M., Katak, A. C., & Singh, A. (2014). Primary small cell carcinoma of the larynx. *Clinical Cancer Investigation Journal*, 3(6), 542-544. doi:10.4103/2278-0513.142664
- Shaw, R., & Beasley, N. (2016). Aetiology and risk factors for head and neck cancer: United Kingdom National Multidisciplinary Guidelines. *J Laryngol Otol*, 130(S2), S9-S12. doi:10.1017/S0022215116000360
- SM, B., DL, B., M, M. M., A, H., A, S., & DL, G. (2010). Should extrapulmonary small cell cancer be managed like small cell lung cancer? *Cancer*, 116(4).
- Stedman, T. L. (1990). *Stedman's Medical Dictionary (Vol. Cancer Medicine)*. New York, New York, U.S.A.: Macmillan Pub Co, 1990.
- Sturgis, E. M., & Pytynia, K. B. (2005). After the smoke clears: environmental and occupational risks for carcinoma of the upper aerodigestive tract. *Cancer J*, 11(2), 96-103.
- Tezal, M., Sullivan Nasca, M., Stoler, D. L., Melendy, T., Hyland, A., Smaldino, P. J., . . . Loree, T. R. (2009). Chronic periodontitis-human papillomavirus synergy in base of tongue cancers. *Arch Otolaryngol Head Neck Surg*, 135(4), 391-396. doi:10.1001/archoto.2009.6
- Thompson, D. H., Kao, Y. H., Klos, J., Fay, J., & Fetter, T. W. (1982). Primary small cell (oat cell) carcinoma of the larynx associated with an IgD multiple myeloma. *Laryngoscope*, 92(11), 1239-1244.
- Wang, Z., Sun, H., & Yakisich, J. S. (2014). Overcoming the blood-brain barrier for chemotherapy: limitations, challenges and rising problems. *Anticancer Agents Med Chem*, 14(8), 1085-1093.
- Zainuddin, N., & Mohd Kornain, N. K. (2016). Glottic cancer in a non-smoking patient with laryngopharyngeal reflux. *Malays Fam Physician*, 11(2-3), 35-37.
- Zhu, Y., Gao, L., Meng, Y., Diao, W., Zhu, X., Li, G., . . . Chen, X. (2015). Laryngeal Neuroendocrine Carcinomas: A Retrospective Study of 14 Cases. *Biomed Res Int*, 2015, 832194. doi:10.1155/2015/832194